MEME KANSERİ SLN BİYOPSİ TEKNİKLERİ AKSİLLER DİSEKSİYON BİTİYOR MU

DR SANCAR BAYAR

AÜTF CERRAHİ ONKOLOJİ BD

AKSİLLER DİSEKSİYON

- KLİNİK VE RADYOLOJİK AKSİLLASI POZİTİF
- ŞÜPHELİ VAKALARDA CORE BİYOPSİ İLE VERİFİKASYON
- NEOADJUVAN PLANLANMIYORSA AKSİLLER DİSEKSİYON

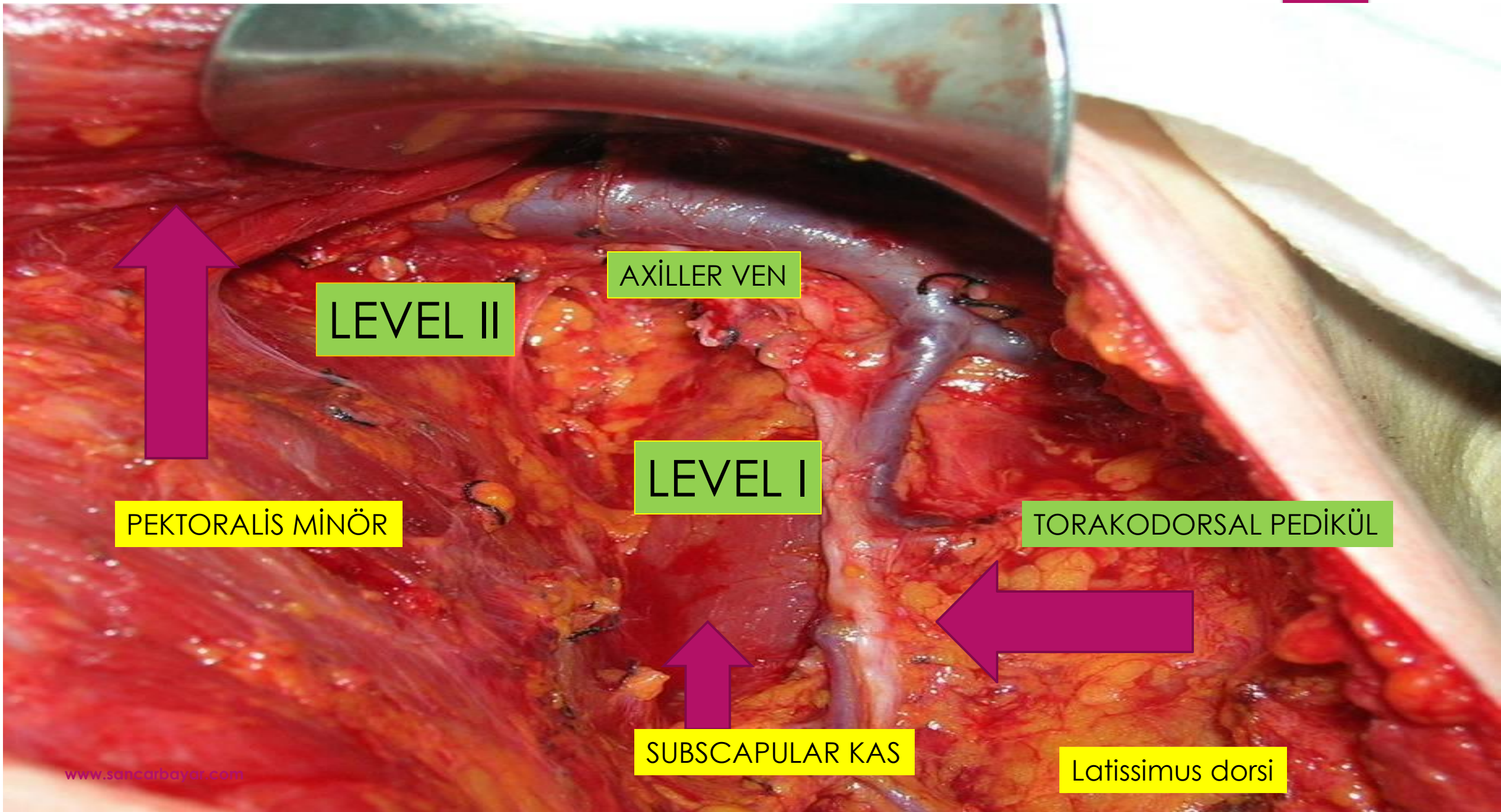
AXİLLER VEN
LEVEL II
LEVEL I
PEKTORALİS MİNÖR
TORAKODORSAL PEDİKÜL
SUBSCAPULAR KAS
Latissimus dorsi
www.sancarbayar.com

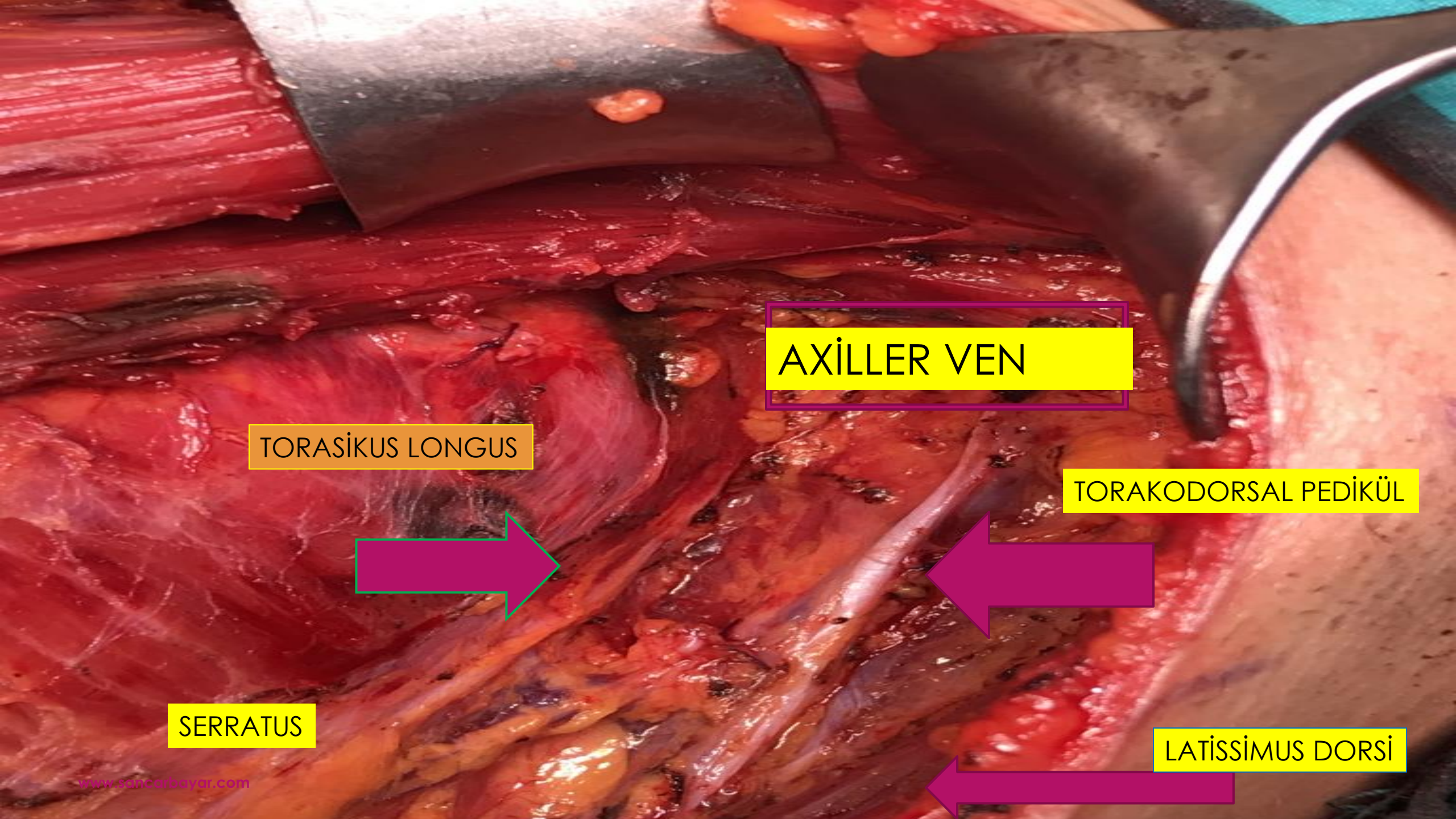
AXİLLER VEN
TORASİKUS LONGUS
TORAKODORSAL PEDİKÜL
SERRATUS
LATİSSİMUS DORSİ
www.sancarbayar.com

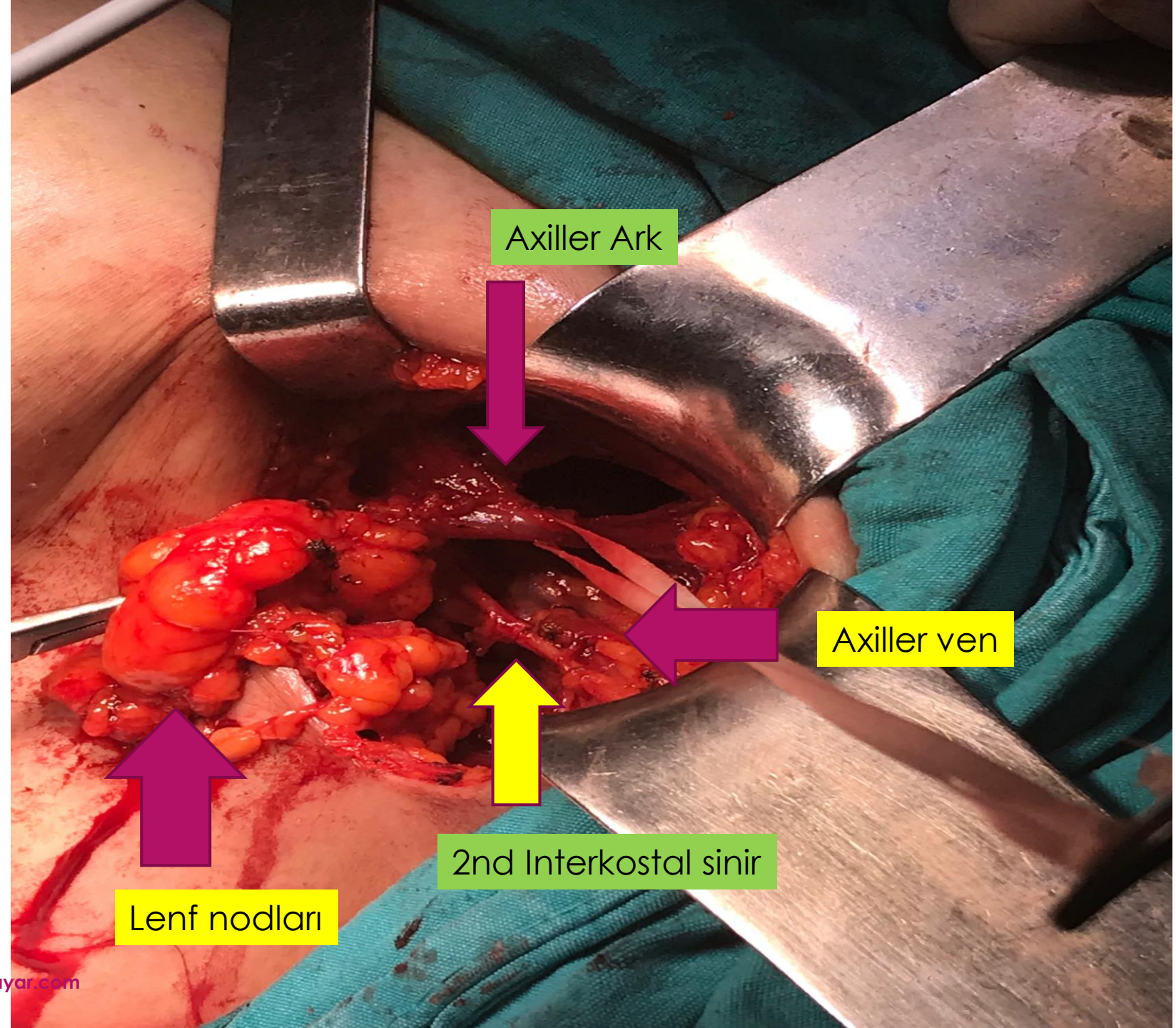

www.sancarbayar.com

AKSİLLER DİSEKSİYON MORBİD BİR GİRİŞİMDİR

- Lenfödem
- Omuz hareketlerinde kısıtlanma
- Kolda ağrı, parestezi
- Torasikus longus ve torakodorsal sinir yaralanmaları

SENTİNEL LENF NODU NEDİR

- Memede sentinel lenf nodu memedeki kanserin muhtemel metastaz yaptığı ilk lenf nodudur
- Sentinel lenf bezinde metastaz yoksa teorik olarak diğer lenf nodlarında da metastaz yoktur
- KLİNİK VE RADYOLOJİK AKSİLLASI NEGATİF HASTALARDA SLN GÜVENİLİR BİR YÖNTEMDİR

İLK UYGULAMALAR

- Krag et al 1993 Gama Probe(%82 SLN IR)
- Giuliano et al 1994 Mavi boya(%93 SLN IR)
- 1998 Massachusetts General Hospital SLN kursu
- DUAL teknik daha başarılı(>%95 IR, FNR <%7)

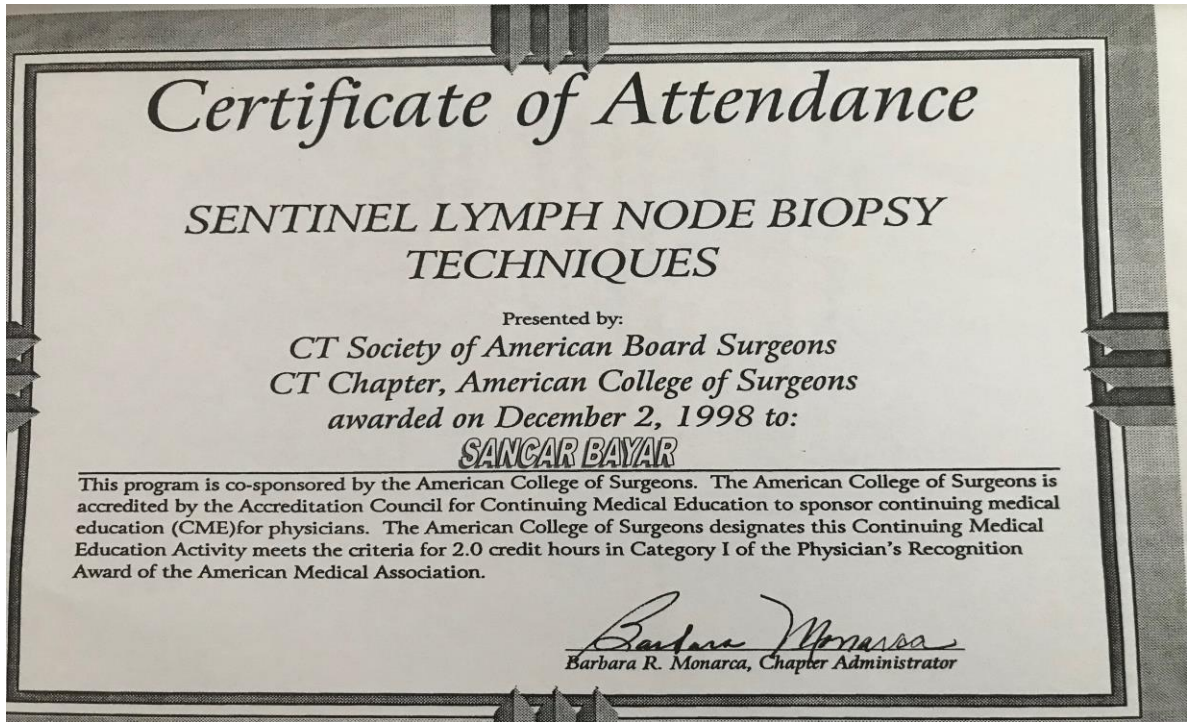

Certificate of Attendance

SENTINEL LYMPH NODE BIOPSY TECHNIQUES

Presented by:
CT Society of American Board Surgeons
CT Chapter, American College of Surgeons
awarded on December 2, 1998 to:
SANCAR BAYAR

This program is co-sponsored by the American College of Surgeons. The American College of Surgeons is accredited by the Accreditation Council for Continuing Medical Education to sponsor continuing medical education (CME)for physicians. The American College of Surgeons designates this Continuing Medical Education Activity meets the criteria for 2.0 credit hours in Category I of the Physician's Recognition Award of the American Medical Association.

Barbara R. Monarca, Chapter Administrator

SLN ONKOLOJİK OLARAK GÜVENİLİR BİR YÖNTEMDİR VE MORBİDİTESİ DAHA AZDIR

- SLN/AKSİLLER DİSEKSİYON arasında onkolojik fark yok
  - Rejyonel kontrol
  - Genel sağ kalım
  - Hastalıksız sağ kalım
- 5 randomize çalışma
  - NSABP B32(2807 ALND, 2804 SLN)
  - MİLAN
  - GIVOM
  - ALMANAC
  - SNAC

SLN POZİTİF HASTALAR

- İzole tümör hücreleri(ITC), <0.2 mm
- Mikrometastaz(0.2mm-2mm)
- Makrometastaz(>2mm)

SLN POZİTİF HASTALARDA YAKLAŞIM

- IBCSG 23-01
- ACOSOG Z0011
- AMAROS

SLN SORUNLU ALANLAR

- Daha önce SLN yapılmış hastalar(%65 IR)
- DCIS(mastektomi, üst dış kadran yerleşimli)
- Multisentrik tümörler? (yapılabilir)
- Inflamatuar meme ca (önerilmiyor)
- Neoadjuvan KT sonrası (özel durumlar)
- Gebeler (Radyonüklid ??)
- Meme küçültme ameliyatı olanlar(Lenfatik yollar değişir)

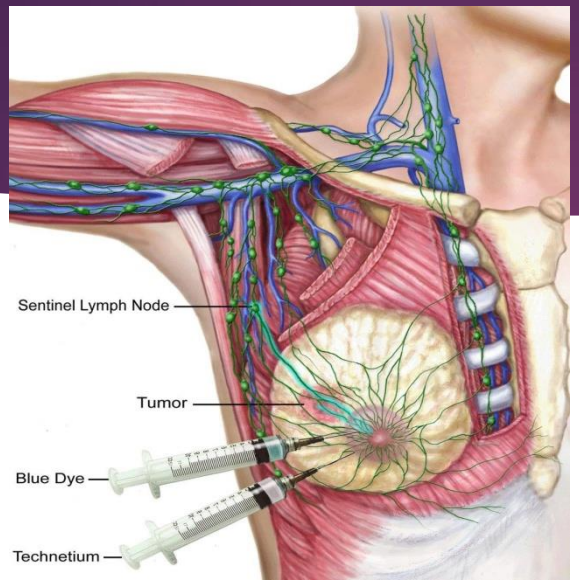
Sentinel Lymph Node
Tumor
Blue Dye
Technetium

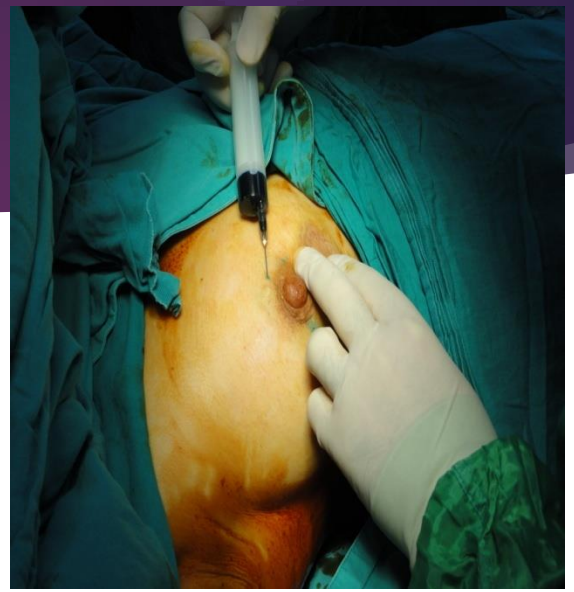

SLN ENDİKASYON VE TEKNİKLER

- Klinik ve radyolojik olarak negatif axilla
- Tc99m Sintigrafi
- Tc99m-Rituximab(CD20 özgü monoklonal antikor)
- Mavi boya
    - Isosulfan blue(Alerjik reaksiyon %1)
    - Patent blue
    - Metilen mavisi(Cilt nekrozu)

ENJEKSİYON TEKNİKLERİ

- Subareolar-Intradermal,subdermal
- Peritumoral ıntradermal,subdermal

SUBAREOLAR Tc99m INTRADERMAL ENJEKSİYON

SIEMENS
ECAM



www.sancarbayar.com

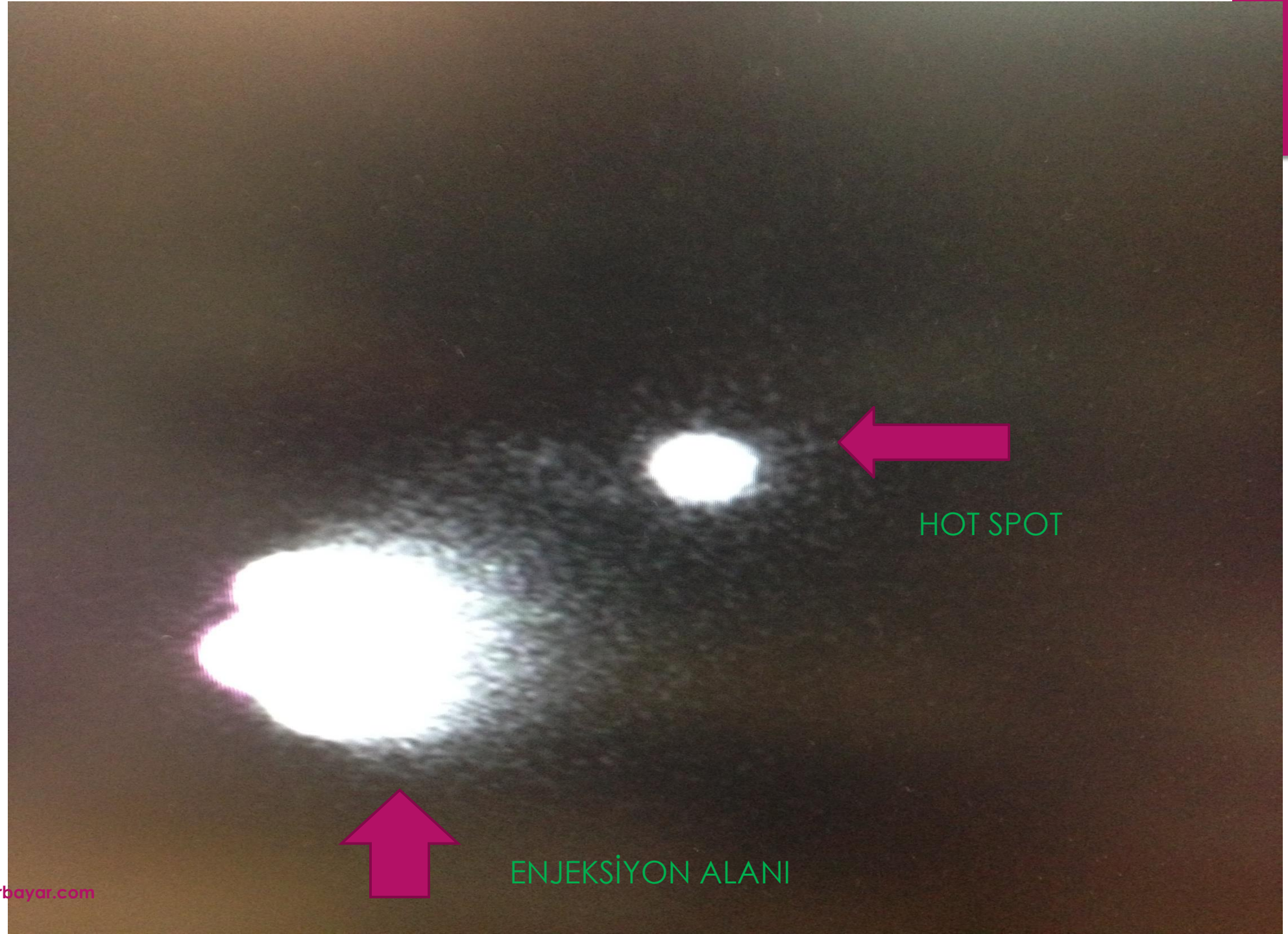
HOT SPOT
ENJEKSİYON ALANI

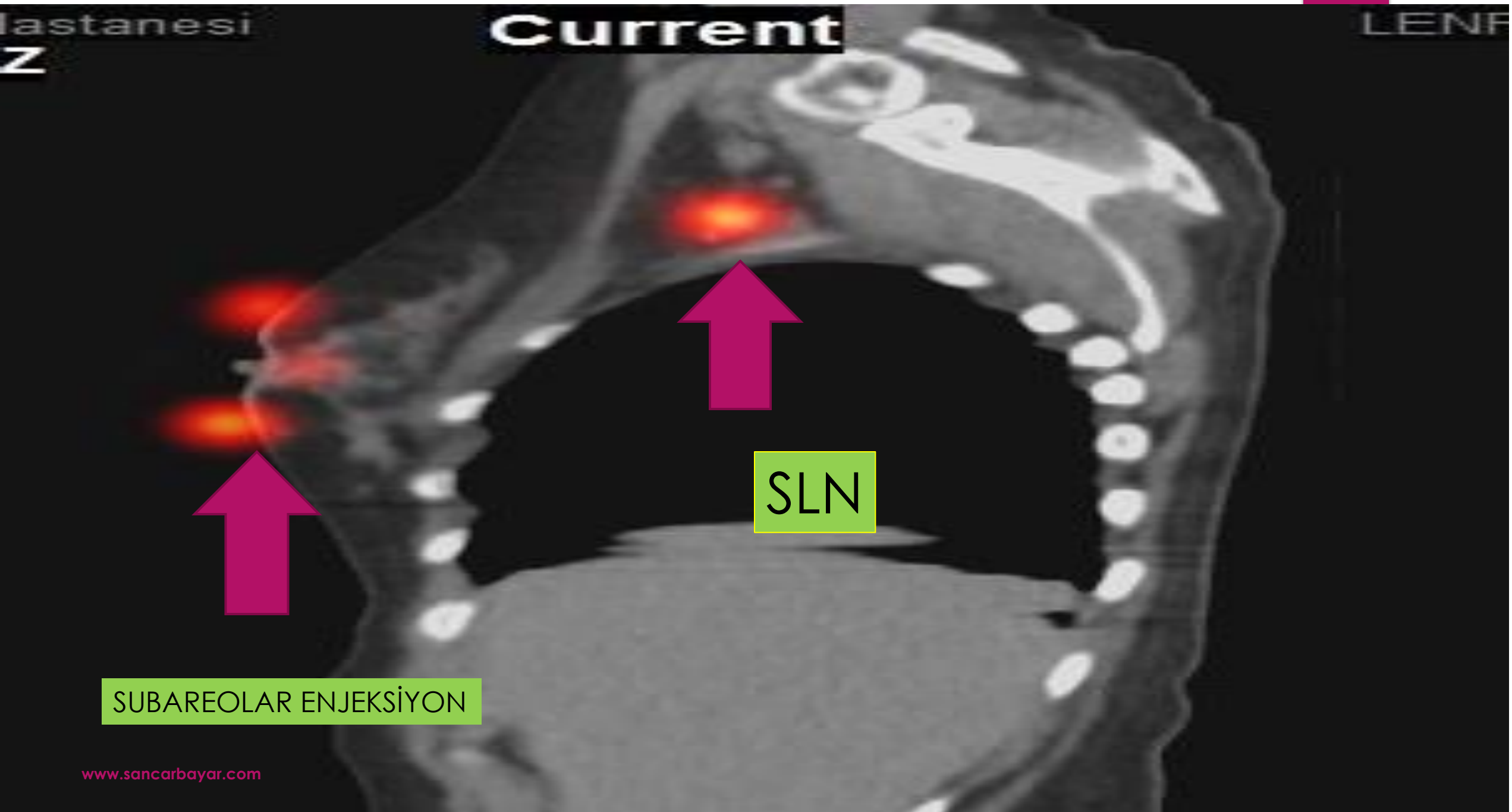
lastanesi
Z
Current
LENF
SLN
SUBAREOLAR ENJEKSİYON

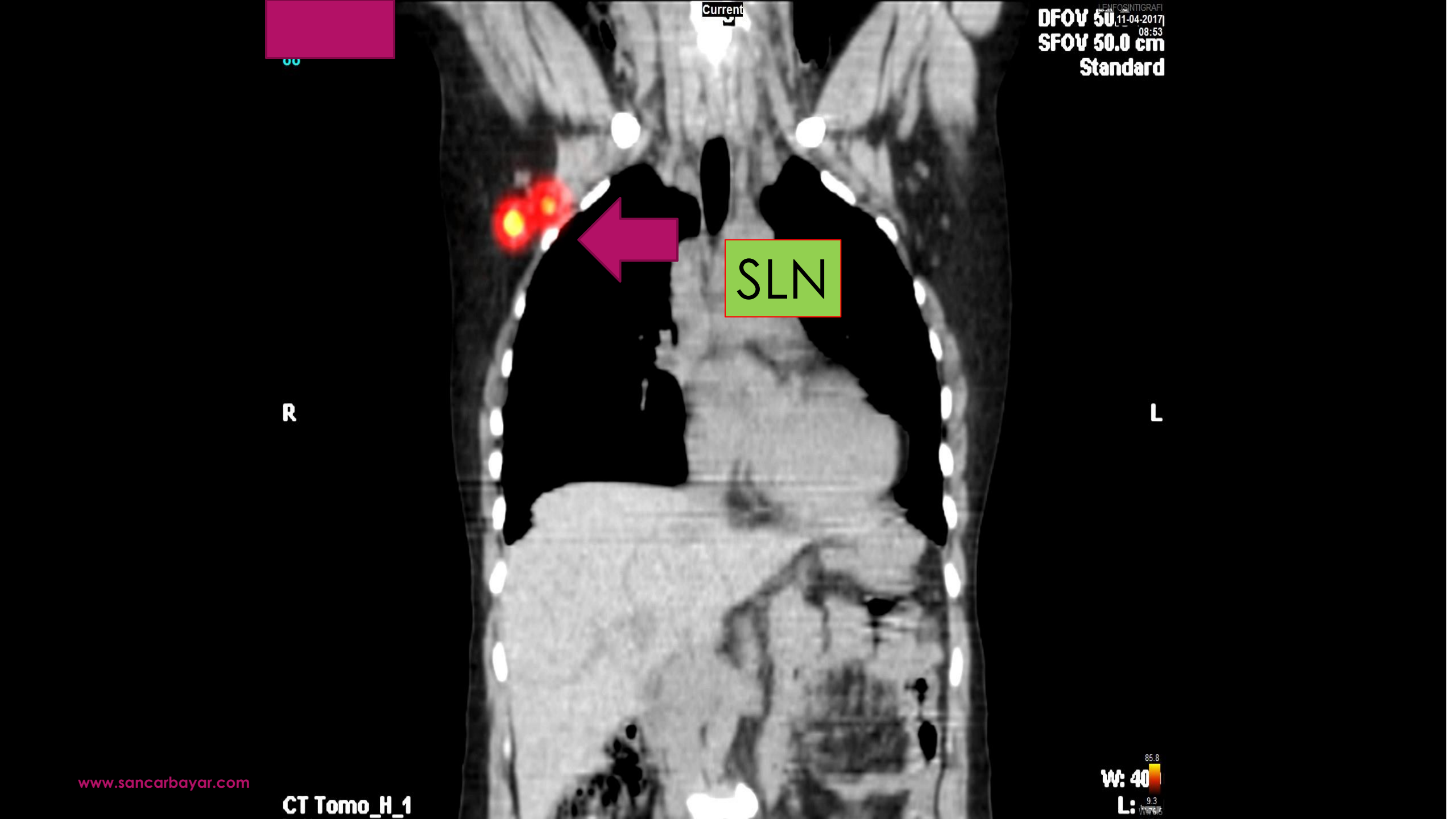
Current
DFOV 50
SFOV 50.0 cm
Standard
11-04-2017
08:53
SLN
R
L
www.sancarbayar.com
CT Tomo_H_1
W: 40
L:

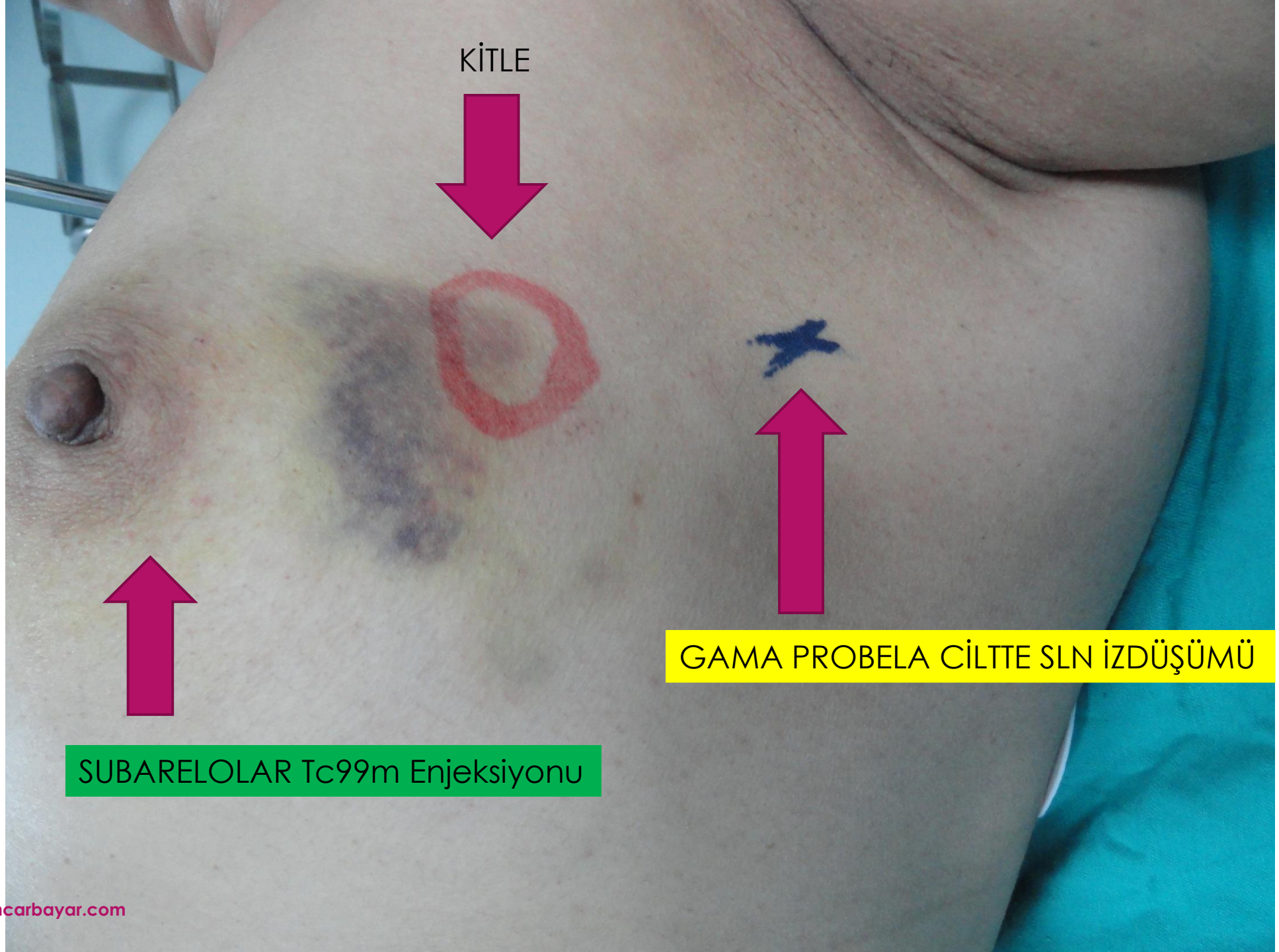
KİTLE
GAMA PROBELA CİLTTE SLN İZDÜŞÜMÜ
SUBARELOLAR Tc99m Enjeksiyonu

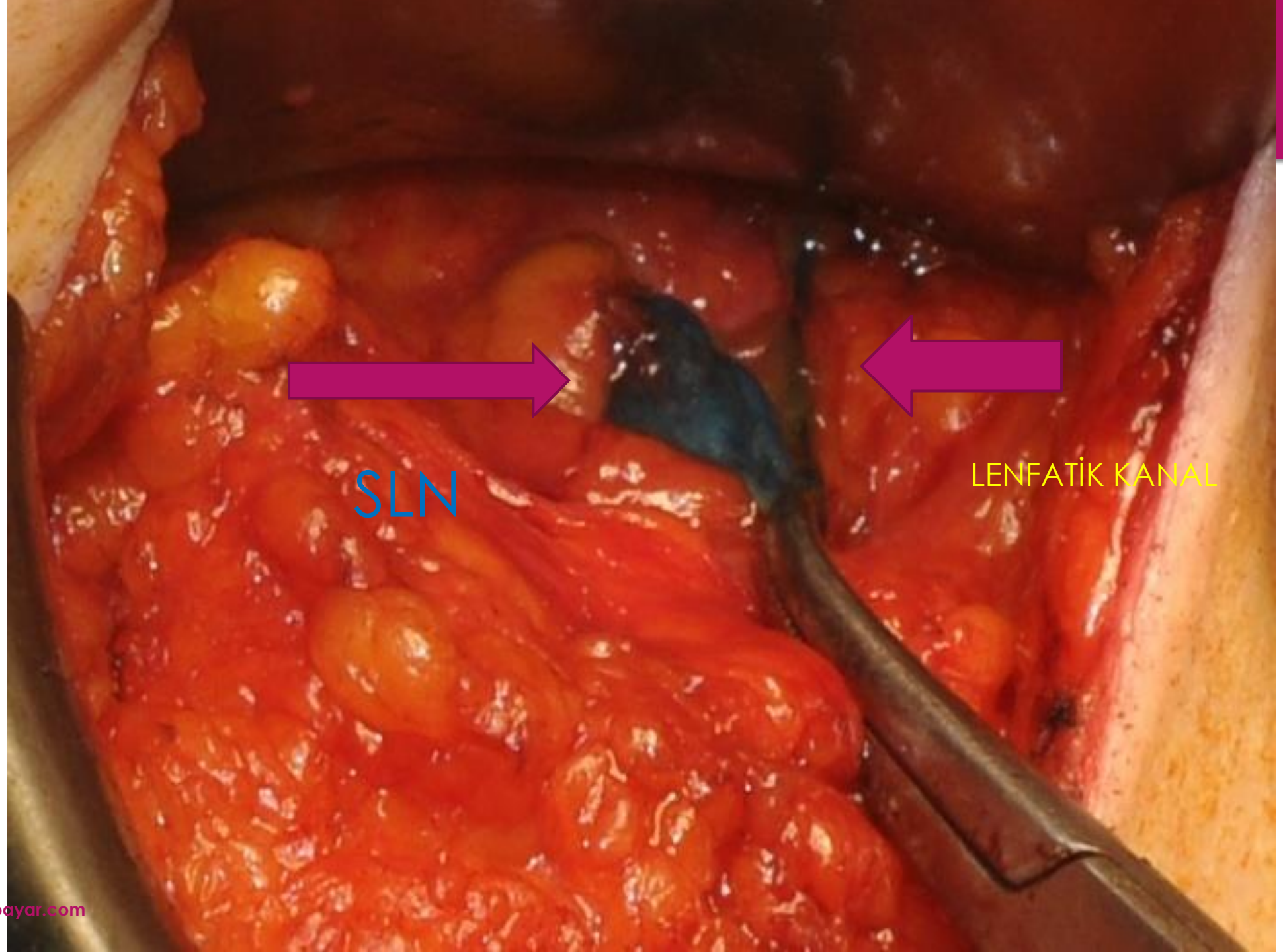
SLN
LENFATİK KANAL

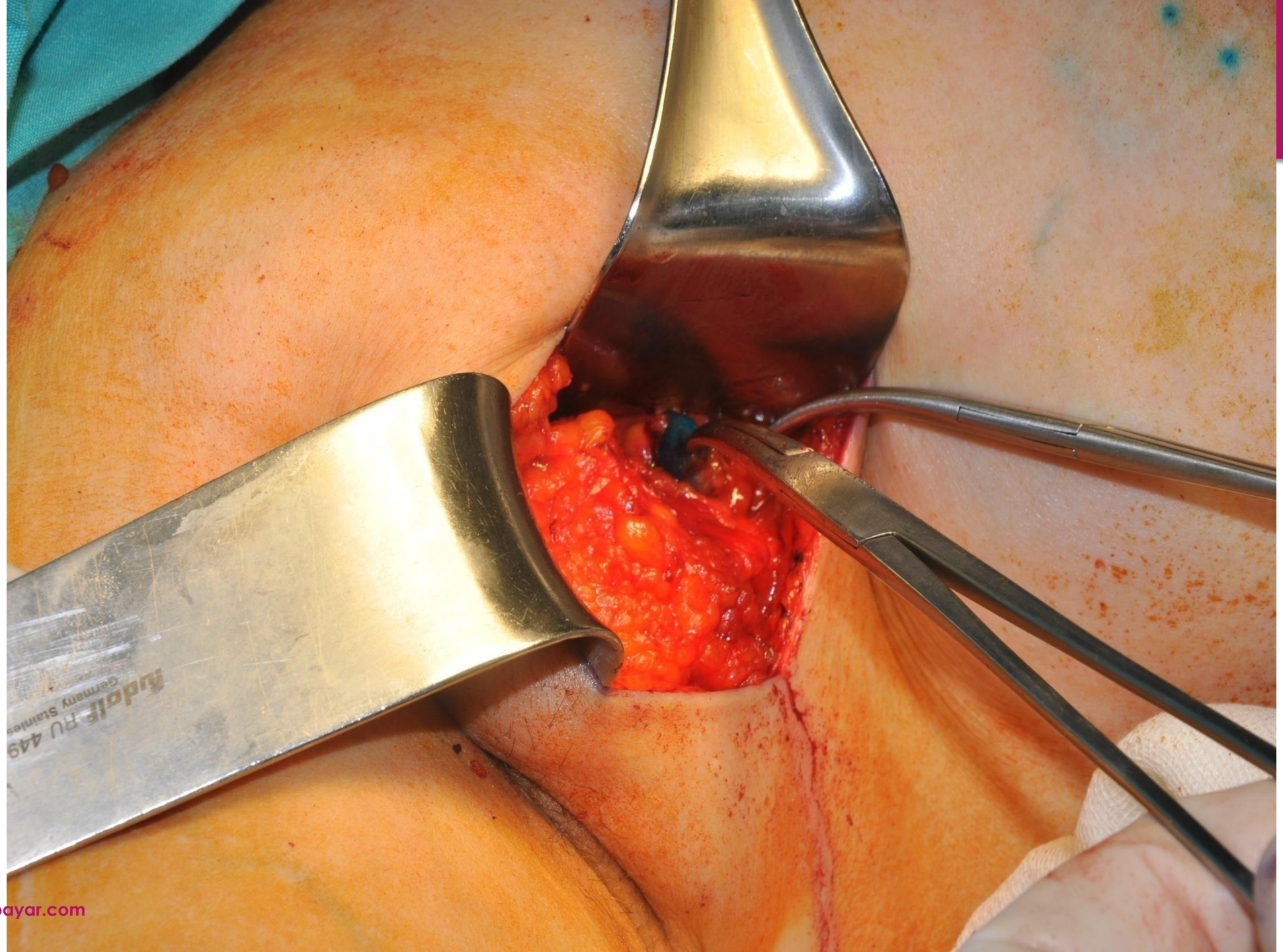
Germany Stainles

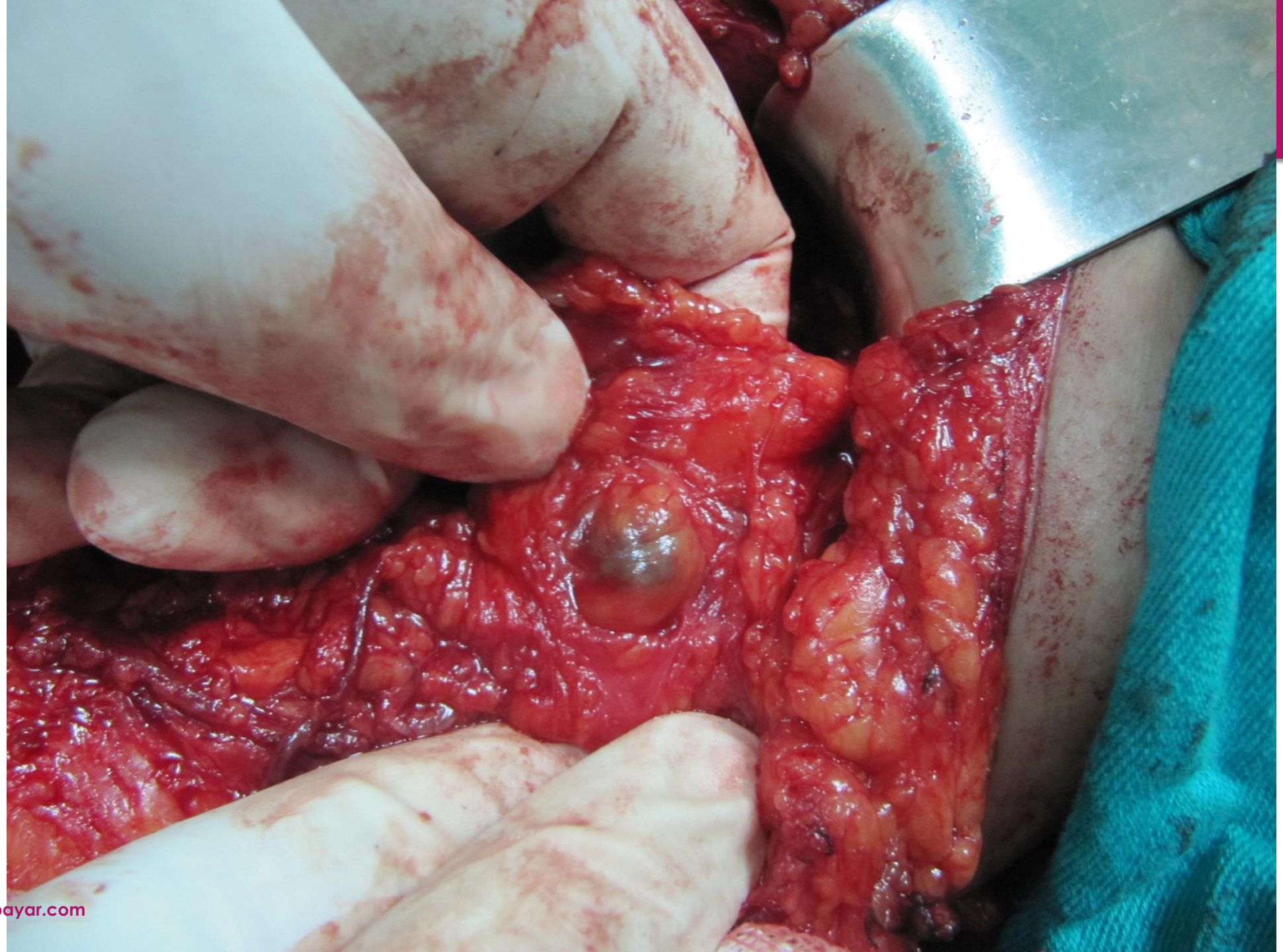

www.sancarbayar.com

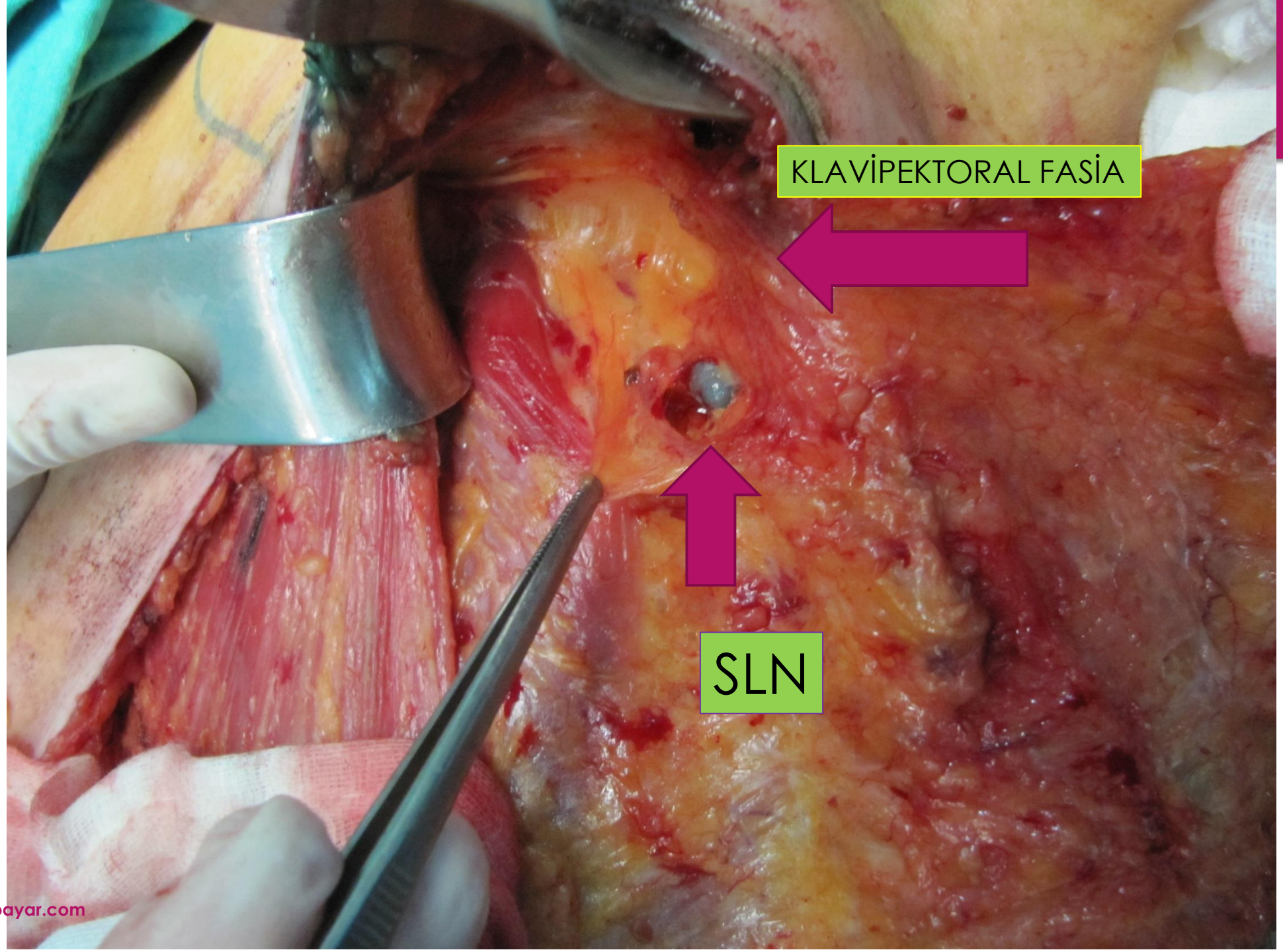
KLAVİPEKTORAL FASİA
SLN

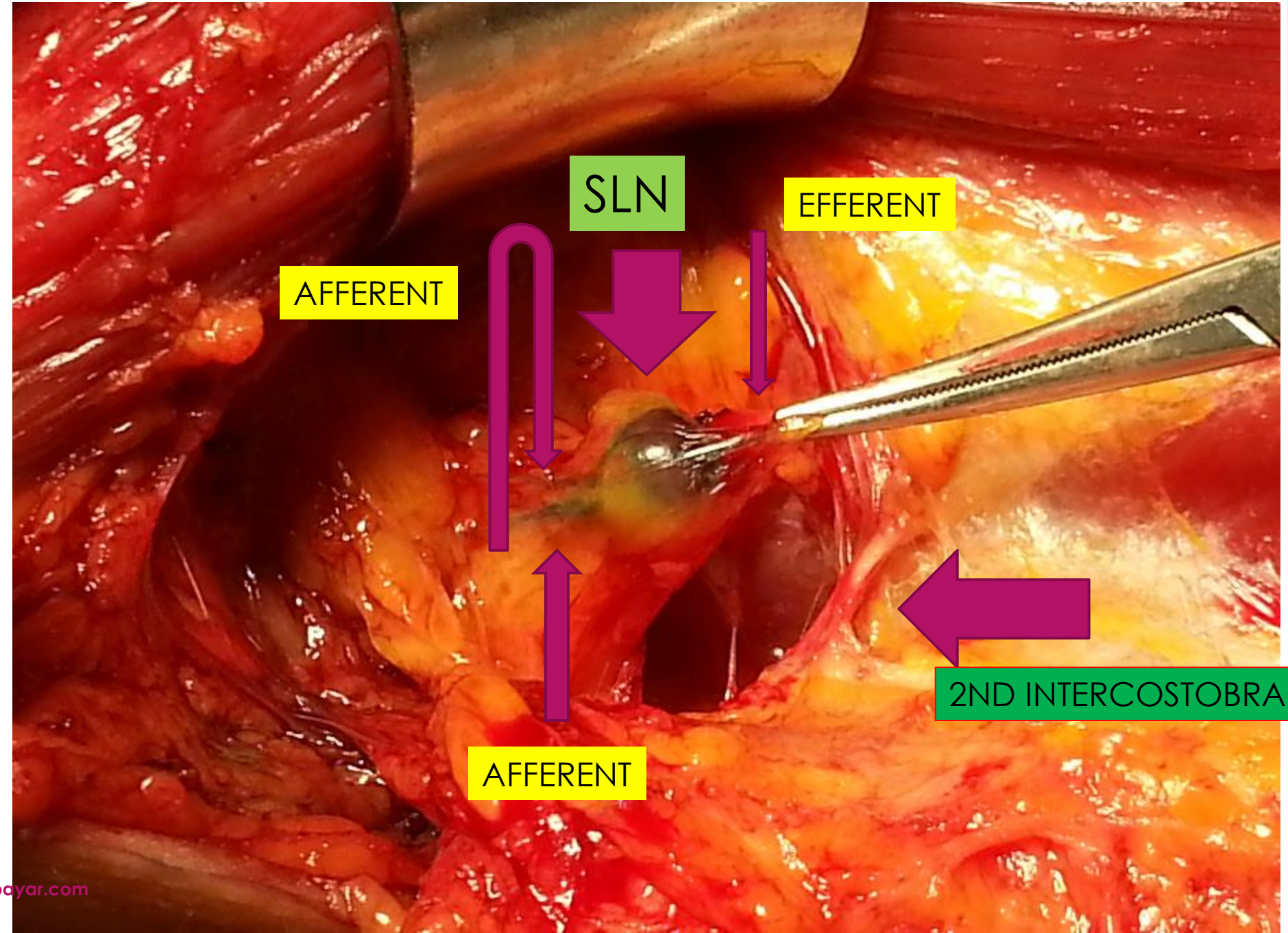
SLN
EFFERENT
AFFERENT
AFFERENT
2ND INTERCOSTOBRACHIAL SİNİR

SLN YENİ YÖNTEMLER

- ICG-Infrared cameras-ICG leak, iyot allerjisi, obezlerde problemli
- ICG-Rituximab(CD20 monoklonal antikor)
- SENTİMAG(2018 FDA Onayı)-metal ekartörlerle etkileşim, MR artefakt, pacemaker, metal implant problemli
- CEUS-Microbubbles(sulfur hexafluoride)
- **99mTc-isosulfan blue(İlem-Özdemir) deneysel model**

ICG SLN

- ICG son 10 yıldır SLN biyopsisinde kullanılıyor
- Optik kamera sistemine ihtiyaç var
- ICG tek başına SLN IR >%95, FNR <%10
- ICG mavi boya ve radyonüklidle kombine edilebilir
- Dual methodda mavi boyanın yerini alabilir, lenfatik kanal ve lenf nodlarını aksiller kesi yapmadan görüntülemek mümkün(Obezlerde görüntüleme sıkıntılı olabilir, 1 cm altında görüntüde azalma)
- Diseksiyonda ICG leak sık izleniyor, ICG-Rituximab da daha az
- ICG-Rituximab da gereksiz LN diseksiyonu daha az
- Allerjik reaksiyon(%0.34) (iyot allerjisi olanlar da kulanılamaz)

ICG SPY SİSTEM

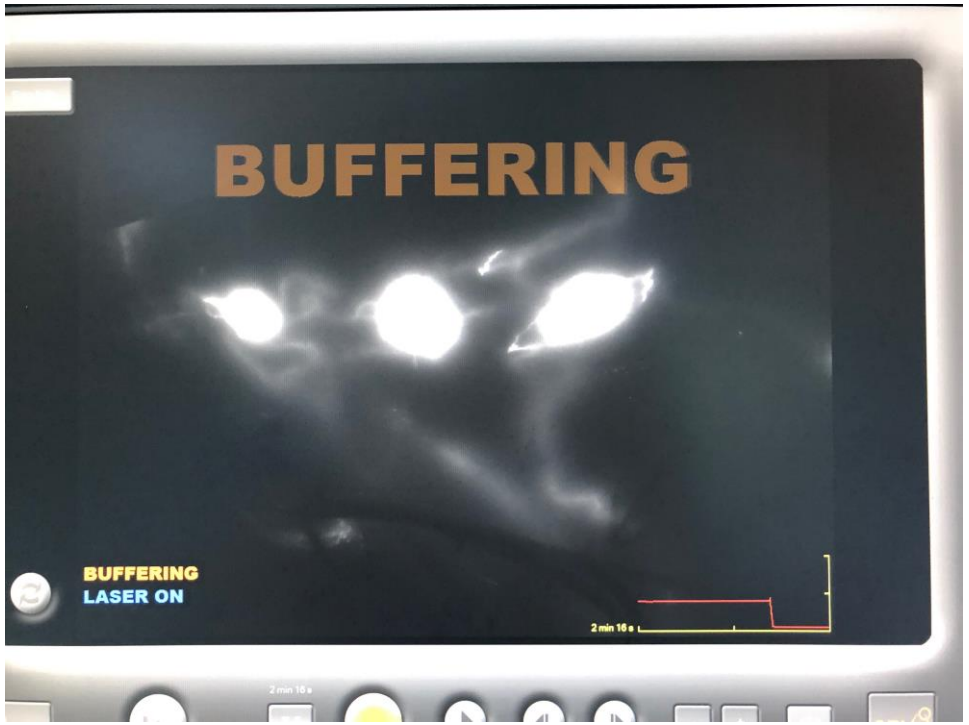

ICG SPY SİSTEM

Table 3
Characteristics of studies using ICG for SLNB.

Patients No.	Method	SLN IR%	SLNB FNR%	Mean SLN removed	Ref.
18	ICG	94	–	2.8	Ahmed et al. (2014)
25	ICG + Indigo carmine	100 (ICG) 92 (BD)	0 (ICG) 25 (BD)	5.4 (ICG) 2.3 (BD)	Ahmed et al. (2014)
10 (Group 1) 20 (Group 2)	Group 1: ICG; Group 2: ICG + ^{99m}Tc-labeled sulphurradiocolloid	97 (ICG) 100 (Combined)	10 (ICG) 23 (RI)	1.8 (ICG) 1.4 (RI)	Ahmed et al. (2014)
113 (Group 1) 29 (Group 2)	Group 1: ICG + Patent blue; Group 2: ICG + ^{99m}Tc-labeled phytateradiocolloid	99.3 (ICG) 100 (RI) 92.9(BD)	–	3.8 (ICG) 2.0 (RI) 1.9 (BD)	Ahmed et al. (2014)
43	ICG	97.7	5.6	2.0	Ahmed et al. (2014)
50	ICG + indigo carmine	100 (ICG) No percentage for BD stated	–	3.7 (ICG)	Ahmed et al. (2014)
312	ICG	100	–	3.4	Ahmed et al. (2014)
128	ICG + indigo carmine	100 (ICG) 66 (BD)	0 (ICG) 42 (BD)	3.1 (ICG) 1.0 (BD)	Ahmed et al. (2014)
47	ICG	98	5.3	2.0	Ahmed et al. (2014)
28 (Group 1) 21 (Group 2)	Group 1: ICG + ^{99m}Tc-labeled radiocolloid; Group 2: ICG:HSA + ^{99m}Tc-labeled radiocolloid	96 (ICG) No percentage for RI stated	–	–	Ahmed et al. (2014)
12 (Group 1) 12 (Group 2)	Group 1: ICG + ^{99m}Tc-labeled radiocolloid + patent blue; Group 2: ICG:HSA + ^{99m}Tc-labeled radiocolloid	96 (ICG) 96 (RI) No percentage for BD stated	–	1.6 (ICG) 1.6 (RI) No percentage for BD stated	Ahmed et al. (2014)
100	ICG + ^{99m}Tc-labeled radiocolloid + Patent blue	100 (ICG) 91.3 (RI) 99 (BD)	–	1.9 (ICG) 1.5 (RI) 1.84 (BD)	Ahmed et al. (2014)
32	ICG-^{99m}Tc-labeled radiocolloid + Patent blue	100 (ICG) 100 (RI) No percentage for BD stated	–	1.5 (ICG) 1.5 (RI) No percentage for BD stated	Ahmed et al. (2014)
99	ICG + indigo carmine	99 (ICG) 78 (BD)	–	3.4 (ICG) No percentage for BD stated	Ahmed et al. (2014)
22	ICG	100	–	2.7	Chi et al. (2014)
393 (Group 1) 108 (Group 2)	Group 1: Sulfan blue; Group 2: ICG + Sulfan blue	99.1 (ICG) 95.0 (BD)	–	2.2 (ICG + BD) 1.6 (BD)	de Boer et al. (2015)
43 (Group 1) 43 (Group 2)	Group 1: ICG + ^{99m}Tc-labeled radiocolloid + Evans blue; Group 2: ^{99m}Tc-labeled radiocolloid	100 (ICG) 100 (RI) 90.7 (BD)	–	–	Kitai et al. (2005)
714	ICG + Patent blue	99.6 (combined)	–	2.4 (combined)	Chi et al. (2013)
96 (Group 1) 73 (Group 2)	Group 1: ICG + patent blue; Group 2: patent blue	96.9 (group 1) 84.9 (group 2)	3.4 (group 1) 11.1 (group 2)	3.8 (group 1) 2.4 (group 2)	Hirano et al. (2012)
27 (Group 1) 68 (Group 2)	Group 1: ICG + ^{99m}Tc-labeled radiocolloid + patent blue; Group 2: ICG + ^{99m}Tc-labeled radiocolloid	99 (ICG) No percentage for BD and RI stated	–	1.9 (ICG) No percentage for BD and RI stated	Jung et al. (2014)
86	ICG + patent blue	93 (ICG) 98.8 (combined)	12 (ICG) 4 (combined)	2.4 (ICG) 3.6 (combined)	Inoue et al. (2016)
36 (Group 1) 32 (Group 2)	Group 1: ICG; Group 2: patent blue	97.2 (ICG) 81.3 (BD)	5.3 (ICG) 6.6 (BD)	3.6 (ICG) 2.1 (BD)	Tong et al. (2014)
301	ICG + ^{99m}Tc-labeled radiocolloid	98.7 (ICG) 95.4 (RI)	–	2.0 (ICG) 2.0 (RI)	Verbeek et al. (2014)
168	ICG + Indigo carmine	100 (ICG) No percentage for BD stated	–	3.0 (median)	Guo et al. (2014a)
821	ICG + ^{99m}Tc-labeled radiocolloid	97.2 (ICG) 97 (RI) 99.8 (combined)	–	> 2.3 (ICG) 1.7 (RI) 2.4 (combined)	Guo et al. (2014b)

IR: identification rate; FNR: false-negative rate; RI: radioisotope; BD: blue dye; ICG: indocyanine green; SLN: sentinel lymph node; SLNB: sentinel lymph node biopsy.

SPIO(SUPERPARAMAGNETIC IRON OXIDE)-SENTIMAG

The Breast 23 (2014) 175–179

Contents lists available at ScienceDirect

The Breast

journal homepage: www.elsevier.com/brst

Original article

The Central-European SentiMag study: Sentinel lymph node biopsy with superparamagnetic iron oxide (SPIO) vs. radioisotope

Marc Thill [a,*], Andrzej Kurylcio [b], Rebekka Welter [c], Viviana van Haasteren [a], Britta Grosse [a], Gilles Berclaz [d], Wojciech Polkowski [b], Nik Hauser [c]

[a] Department of Gynaecology and Obstetrics, Breast Cancer Centre, Agaplesion Markus Hospital, Frankfurt, Germany
[b] Department of Surgical Oncology, Medical University of Lublin, Poland
[c] Department of Gynecology and Obstetrics, Interdisciplinary Breast Centre, Kantonsspital Baden, Baden, Switzerland
[d] Breast Centre Bern, Engeriedspital, Lindenhofgruppe, Bern, Switzerland

ARTICLE INFO

Article history:
Received 1 September 2013
Received in revised form
24 November 2013
Accepted 5 January 2014

Keywords:
Invasive breast cancer
Sentinel lymph node biopsy
Superparamagnetic iron oxide (SPIO)
SentiMag®
Sienna+®

ABSTRACT

Sentinel lymph node biopsy (SLNB) is the standard surgical procedure for the axilla in early node-negative breast cancer. To date, the "gold standard" to localize the sentinel lymph node (SLN) is the radiotracer ^{99m}Tc with or without blue dye. The aim of this study was to evaluate potential equivalency of the new SentiMag® technique in comparison to the "gold standard". Within this prospective, multicentric and multinational non-inferiority study including 150 patients ^{99m}Tc was compared with the magnetic technique, using superparamagnetic iron oxide particles (SPIOs, Sienna+®) for localization of SLNs. The results showed a detection rate per patient of 97.3% (146/150) for ^{99m}Tc vs. 98.0% (147/150) for Sienna+® with a similar average number of removed SLNs per patient and a higher per patient malignancy detection rate for the SPIO tracer. We obtained convincing results that magnetic SLNB can be performed easily, safely and equivalently well in comparison to the radiotracer method.

© 2014 The Authors. Published by Elsevier Ltd. Open access under CC BY-NC-ND license.

SENTIMAG

- 2018 FDA onayı
- 2 ML SİENNA 3 ml salinle dilüe edilip subareolar enjekte edilir
- Cerrahiden 5-20 dk önce
- Magnetometer ile SLN aranır
- Metal ekartör, kalp pili etkileşim
- MR da artefakt
- Demir ve dextran allerjisinde kullanılamaz
- SLN IR %97
- NCT02249208 NAC öncesi aksilla pozitif olup negatife dönenlerde radcol-mavi boya, RADCOL-SPIO, SPIO tek başına FNR açısından karşılaştırılıyor

AVANTAJ-DEZAVANTAJLAR

- Nükleer tıp merkezi gerektirmez
- Ciltte renk değişikliği
- Allerjik reaksiyon
- Kalp pili, metalllerle etkileşim
- MR da artefakt
- Demir depo hastalıkları?

CEUS-Microbubbles

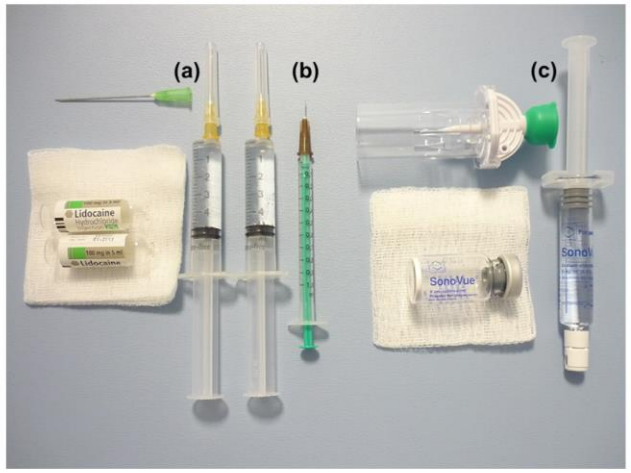

Figure 1 The materials needed for the microbubble study; two sets of 5 ml 1% lidocaine with 26 and 21 G needles (a), which were used for local anaesthesia. Microbubble suspension (0.3 ml) was injected using a 1 ml tuberculin syringe (b). An opened Sonovue™ package with its contents (c) was shown.

Figure 2 Microbubbles were injected intradermally in the upper outer quadrant position of the areola.

Clinical Radiology 67 (2012) 687e694

CEUS SLN CORE BİYOPSİ

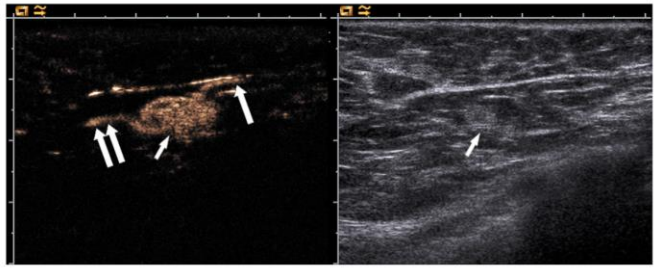

Figure 14 Afferent (single large arrow) and efferent (double large arrows) lymphatic vessels were visualized on the CPS view. The same node (arrow) was noted on grey-scale image.

Figure 15 CPS view clearly showed an enhancing node (small arrow), from which a biopsy was taken. The core biopsy needle (large arrow) can easily be seen on this view as well. This node (arrows) was difficult to identify on grey-scale image.

Clinical Radiology 67 (2012) 687e694

Preparation of ^{99m}Tc-isosulfan blue for lymph node localization in rats

^{99m}Tc-isosulfan blue for lymph node localization

Derya İlem-Özdemir[a,*], Ulkem Yararbas[b], Baha Zengel[c], Gökhan Ertan[d], Makbule Asikoglu[a]

D. İlem-Özdemir et al. Applied Radiation and Isotopes 118 (2016) 338–342

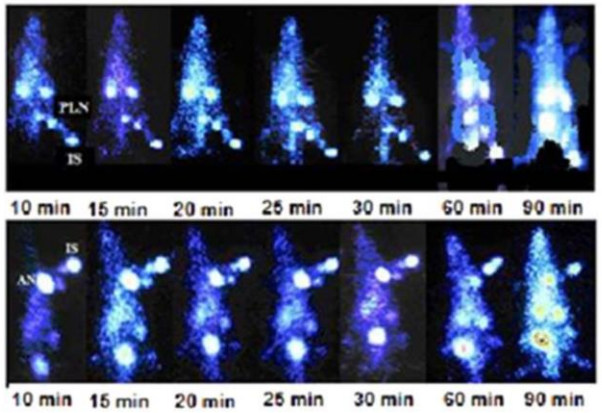

Fig. 3. Scintigrams show supine position of rat in 10, 15, 20, 25, 30, 60 and 90 min after subcutaneous injection of ^{99m}Tc-ISB (AN: Axillary Node, PLN: Popliteal Lymph Node IS: Injection Site).

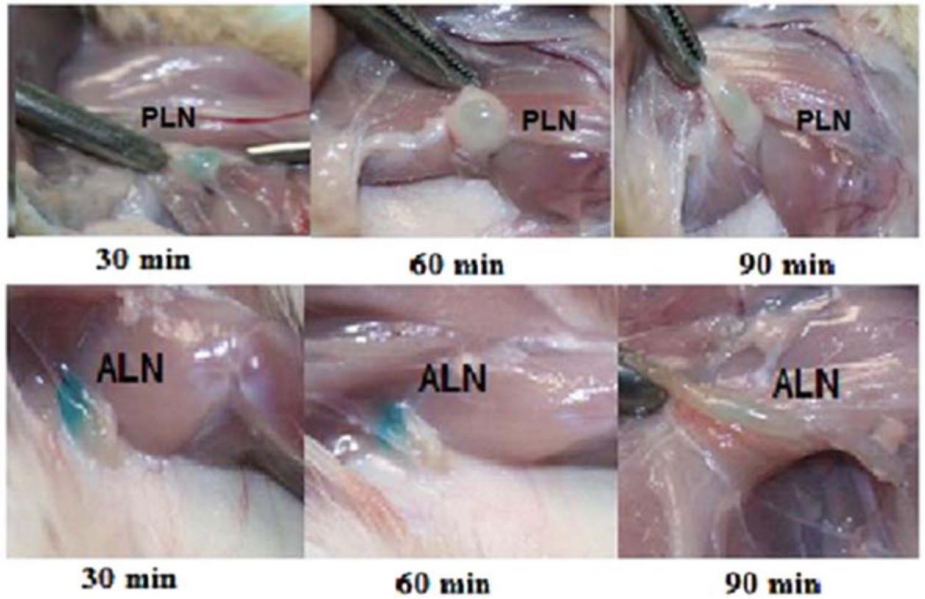

Fig. 4. Image of ALN and PLN of rats 30, 60 and 90 min after injection.

Critical Reviews in Oncology / Hematology 123 (2018) 83–94

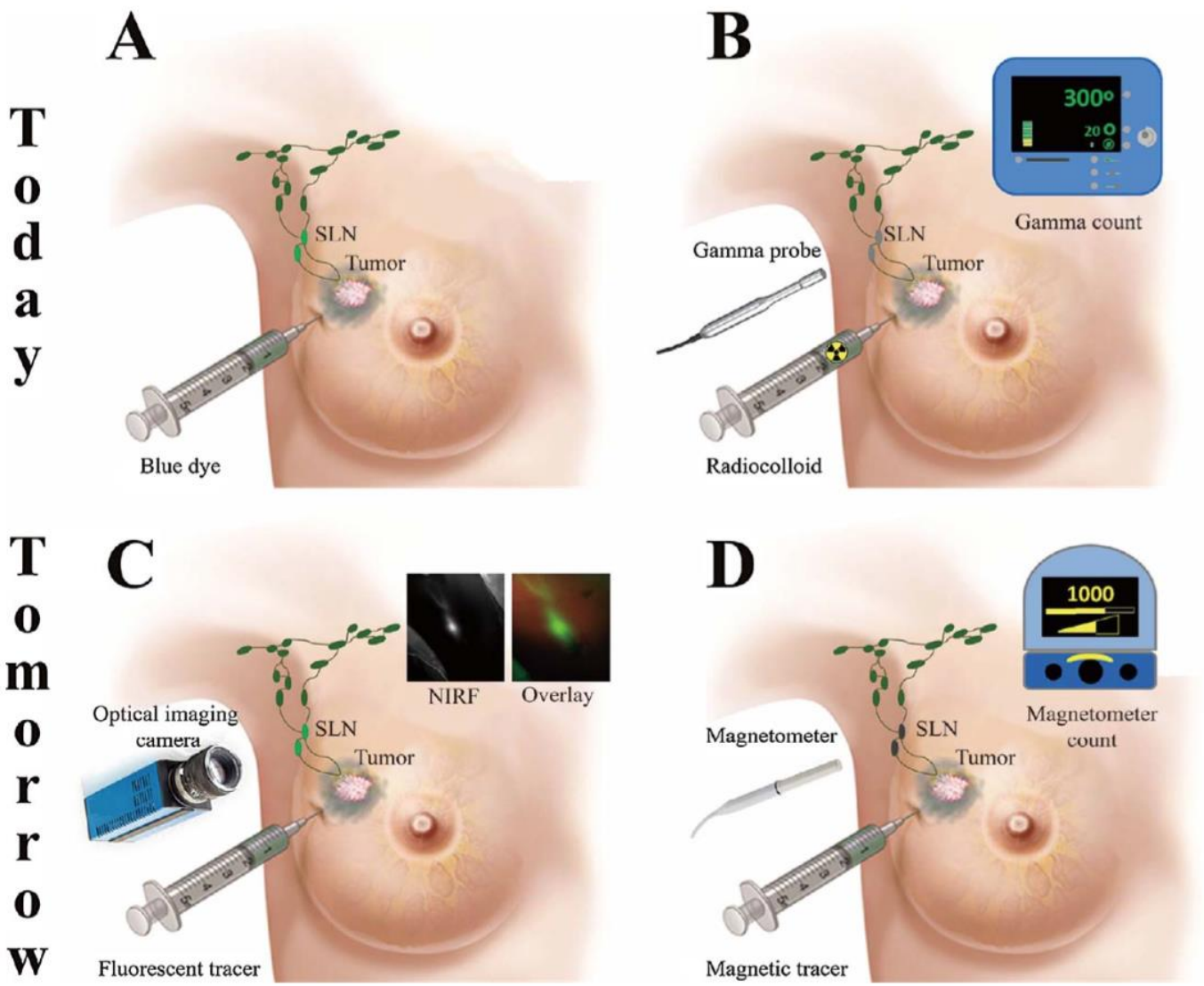

Fig. 1. Four sentinel lymph node (SLN) detecting methods. (A & B) current standard of care for SLN detection: A) the blue dye method relies on the visual detection of the blue stained SLNs; B) the radioisotope method locates the SLNs by using a gamma probe for detecting the radiation emitted from the radioactive tracer accumulated in the SLNs. (C & D) novel methods for SLN detection: C) optical imaging guided SLN detection provides a real-time map for locating the SLNs; D) magnetic tracer guided SLN detection locates the SLNs by using a hand-held magnetometer to magnetize the magnetic tracer and detect the particles' magnetic response.

FROZEN



Intraoperatif SLN Değerlendirmesi

- Frozen(Deneyim, Örnekleme sayısı)
- Imprint touch sitoloji(Deneyim, Örnekleme sayısı)
- OSNA(One step nücleic acid amplification)
    - Cytokeratin 19(CK19) mRNA
    - %93.8 Patolojiyle uyumlu sonuç
    - 20-40 dk sonuç alma
    - Mikro/Makro metastaz ayırımı
    - CK19 ekspresyonu olmaması dezavantaj
    - Geriye dönük incelemelerde problem
    - Neoadjuvan KT sonrası önerilebilir

SLN Pozitif Vakalarda Aksiller Diseksiyon(AD) Gereklimi

- ITC SLN aksiller diseksiyon gerekli değil
- IBSCG(International Breast Cancer Study Group) 23-01(2001) SLN mikrometastazda(0.2-2mm) AD gerekli değil(2013)
- ACOSOG Z0011 T1-2 tümörlerde MKC yapılmışsa SLN + (≤2) vakalarda AD gerekli değil (2017)
- AMAROS SLN + (≤2) vakalarda AD yerine aksiller RT yapılabilir, lenfödem daha az
- SOUND T1 tümörlerde US normalse SLN gerekli değildir??

ACOSOG Z0011 ZAYIF YÖNLERİ

- Hastaların tamamı MKC yapılmış hastalar
- Mastektomili hasta yok
- %83 ER pozitif
- Tangential RT yapılmış, aksillaya verilen RT belirsiz, standart yok
- SLN %50 mikrometastaz

AMAROS ZAYIF YÖNLERİ

- %77 TEK POZİTİF SLN
- %40 MİKROMETASTATİK
- Hastaların çoğu Z0011 çalışmasına uygun(aksiller tx gerekmiyor)
- %40 hastada aksiller US yapılmamış
- Lenfödem daha az, omuz mobilitesi benzer
- Uzun dönem RT Toksisitesi(Brakial plexus hasarı)??

POSNOC: A Randomised Trial Looking at Axillary Treatment in Women with One or Two Sentinel Nodes with Macrometastases

A. Goyal *, D. Dodwell †

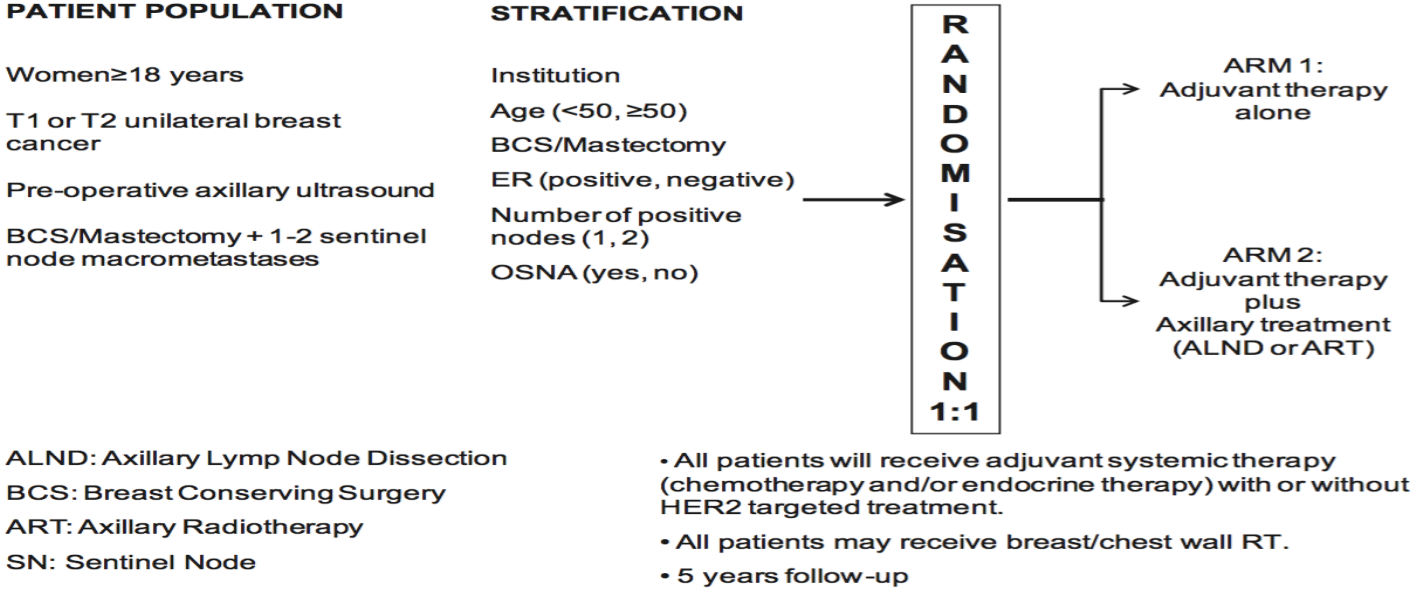

Fig 1. POSNOC trial design.

Clinical Oncology 27 (2015) 692e695

AKSİLLER CERRAHİ SLN DAHİL YAPMASAK MI

- SOUND
- NCT01821768
- INSEMA
- SNBO >70

NCCN 2018 AKSİLLER EVRELEME

National Comprehensive Cancer Network®

NCCN Guidelines Version 3.2018
Invasive Breast Cancer

NCCN Guidelines Index
Table of Contents
Discussion

SURGICAL AXILLARY STAGING - T0,N1,M0; T1-3,N0-1,M0 DISEASE

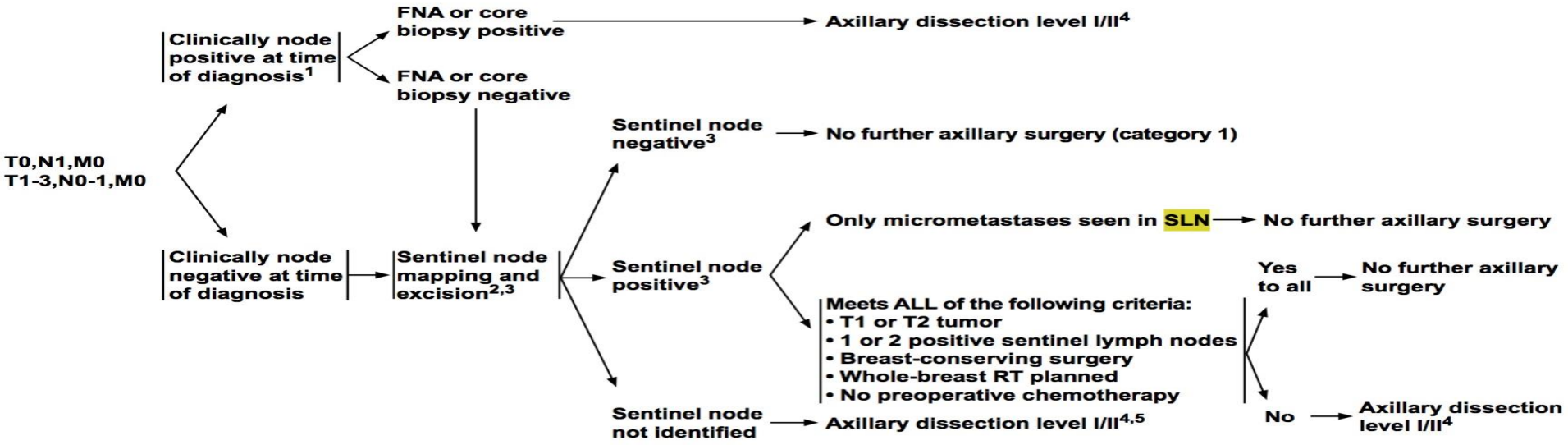

[1]Consider pathologic confirmation of malignancy in clinically positive nodes using ultrasound-guided FNA or core biopsy in determining if a patient needs axillary lymph node dissection.
[2]Sentinel lymph node mapping injections may be peritumoral, subareolar, or subdermal.
[3]Sentinel node involvement is defined by multilevel node sectioning with hematoxylin and eosin (H&E) staining. Cytokeratin immunohistochemistry (IHC) may be used for equivocal cases on H&E. Routine cytokeratin IHC to define node involvement is not recommended in clinical decision-making.

[4]See Axillary Lymph Node Staging (BINV-E).
[5]For patients with clinically negative axilla who are undergoing mastectomy and for whom radiation therapy is planned, axillary radiation may replace axillary dissection level I/II for regional control of disease.

NCCN 2018 NEOADJUVAN KT AKSİLLER DEĞERLENDİRME

National Comprehensive Cancer Network®

NCCN Guidelines Version 3.2018
Invasive Breast Cancer

NCCN Guidelines Index
Table of Contents
Discussion

PREOPERATIVE SYSTEMIC THERAPY: BREAST AND AXILLARY EVALUATION

Preoperative systemic therapy planned →

Core biopsy of breast with placement of image-detectable marker(s), if not previously performed, must be done to demarcate the tumor bed for surgical management after preoperative systemic therapy →

Prior to preoperative systemic therapy perform:
- **Axillary imaging with ultrasound or MRI (if not previously done) and**
- **Biopsy of suspicious and/or clinically positive axillary lymph nodes**

→

If ipsilateral axillary lymph node evaluation is negative
- **Sentinel lymph node biopsy (SLNB) is preferably performed after preoperative systemic therapy**

If ipsilateral axillary lymph node biopsy is positive, axilla may be restaged after preoperative systemic therapy;[pp]
- **Axillary lymph node dissection (ALND) should be performed if axilla is clinically positive.**
- **If the axilla is clinically negative after preoperative therapy, SLNB can be performed in selected cases (category 2B)[qq]; otherwise ALND should be performed.**

→ **See Preoperative Systemic Therapy: Surgical Treatment (BINV-13)**

[pp]Marking of sampled axillary nodes with a tattoo or clip should be considered to permit verification that the biopsy-positive lymph node has been removed at the time of definitive surgery.

[qq]Among patients shown to be node-positive prior to preoperative systemic therapy, SLNB has a >10% false-negative rate when performed after preoperative systemic therapy. This rate can be improved by marking biopsied lymph nodes to document their removal, using dual tracer, and by removing more than 2 sentinel nodes.

Note: All recommendations are category 2A unless otherwise indicated.
Clinical Trials: NCCN believes that the best management of any patient with cancer is in a clinical trial. Participation in clinical trials is especially encouraged.

ALINACAK DERSLER

- SLN NEGATİF HASTALARDA AKSİLLER DİSEKSİYON GEREKSİZ
- SLN ITC VE MİKROMETASTAZDA(23-01) AKSİLLER DİSEKSİYON GEREKSİZ
- SLN MAKROMETASTAZDA TARTIŞMA DEVAM EDİYOR, 1-2 METASTAZDA TÜM MEME RT/AKSİLLER RT İLE YAPILABİLİR (Z 11, AMAROS)
- NEOADJUVAN KT SONRASI SLN TARTIŞMALI
  - NEOADJ ÖNCESİ AKSİLLA NEGATİFLERDE SLN YAPILABİLİR
  - NEOADJ ÖNCESİ AKSİLLA POZİTİF, NEAOADJ SONRASI AKSİLLA NEGATİF OLANLARDA SLN TARTIŞMALI (FNR >%10, ÖZEL DURUMLARDA YAPILABİLİR)
    - Z1071, SENTINA,SN FNAC
    - FM, AUS, Dual teknik, >3 SLN (FNR<%10)
    - Pozitif lenf nodları KT ÖNCESİ KLİPLENİR, KT SONRASI I 125 SEED İŞARETLENİR(TAD)

LENFÖDEM CERRAHİSİ-Prof Dr Savaş Serel AÜTF Plastik ve Rekonstrüktif Cerrahi ABD
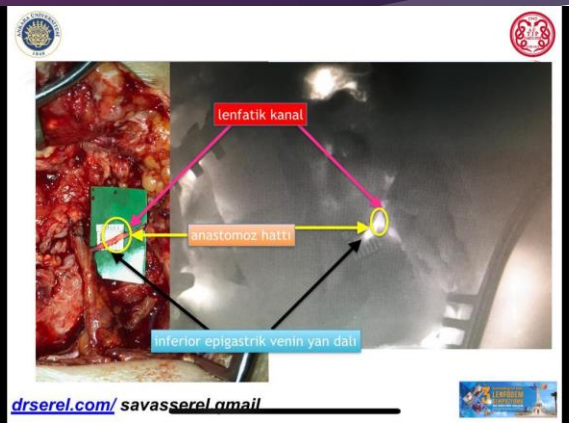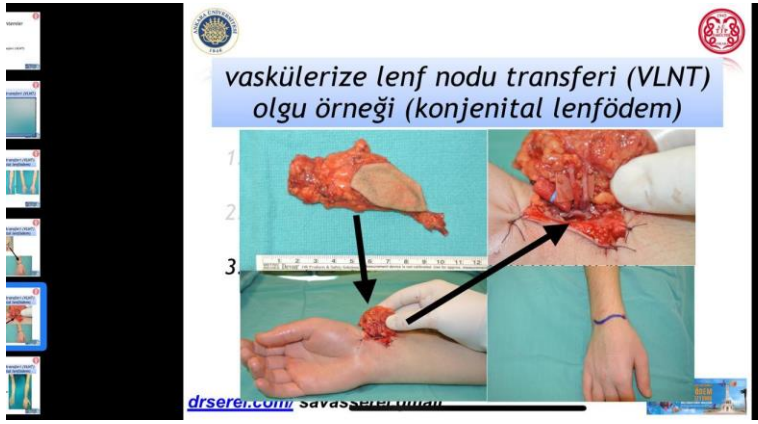
- İzole vaskülarize lenf nodu transferi
- Mastektomili hastalarda DIEP'le birlikte inguinal lenf nodu transferi
- Lenfovenöz anostomoz
- Başarı oranları %60-70